

# INTEREST OF DIPHOTERINE® AS AN OCULAR RINSING SOLUTION FOR THE EMERGENCY TREATMENT OF SERIOUS OCULAR BURN

Presented at SFO congress, Paris, France, May 2002

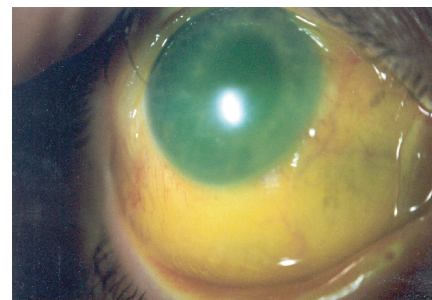
M. GERARD (1), H MERLE (2), F. CHIAMBARETTA (3), D. RIGAL(3), N. SCHRAGE (4)

Service d'Ophtalmologie

(1) Centre Hospitalier de Cayenne, France (2) CHU de Fort de France, France (3) CHU de Clermont Ferrand, France (4) Augenklinik, Aachen, Germany

**INTRODUCTION:** We report a case of serious eye burns (Grade IV of Ropper Hall's classification) healed by a simple conservative therapeutic regimen, preceded by an initial rinsing with one litre of Diphotérine®, one hour after the accident.

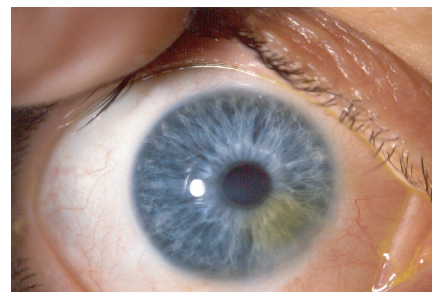
**CASE REPORT:** A 49 year old woman, was aggressed with a chemical product onto her face and eyes. The immediate eye examination, 1 hour after, showed a serious eye burn on the right eye. The visual acuity was 2/20, the cornea was opaque. As a consequence, the iris was hardly distinguishable. The limbus showed a conjunctival and limbal ischemia 360°, with scleral necrosis on the infero-nasal region. The corneal epithelium was completely removed. An immediate rinsing was started one hour after the accident. We used one liter of Diphotérine®. Further treatment consisted in instillation of 2 drops of a combination demamethasone and neomycin. An immediate anterior chamber puncture followed. The eye burn grade IV of Ropper Hall's classification was confirmed (Figure 1). We continued topical corticosteroids eye drops every 20 minutes for 3 more hours. The consecutive therapy regimen consisted in dexametasone eye drops, indometacin, antibiotics and ascorbate eye drops 6 times per day, and atropine. This medication was complemented with high doses of oral ascorbate (3g/day). An antisymblepharon ring was placed. The evolution with a progressive reepithelialisation took place within 21 days. The corneal surface was irregular and showed a punctuate keratopathy pattern. An infero-nasal stromal edema persisted. We added tear substitutes. On day 35, we noticed a corneal inferonasal ulcer. We stopped the local corticosteroid and restarted antibiotic treatment. The ulcer increased its size and the stromal oedema enlarged. New vessels appeared on this site. At this point, we started the local corticosteroids with fluorometholone 6 times a day again. On day 42, we noticed a decrease of the stromal oedema and the ulcer size. On day 56, we stopped the rifamycin eye drops when we saw an orange impregnation of the corneal stroma. The cornea became fluorescein stains negative and non edematous on day 97. In the infero-nasal region, the neovascularisation was progressed to day 180, and is now stable (Figure 2). The visual acuity is currently 14/20.



**Figure 1:** Initial examination of the right eye after rinsing by Diphotérine (1 hour after the accident): Importance of stromal oedema. Conjunctival and limbal ischemia 360°; scleral necrosis on the infero-nasal region.

**DISCUSSION :** We are reporting here a clinical case with healing after a serious chemical ocular burn. Among the numerous factors involved in this healing, it seems important for us to underline the initial ocular external rinsing with Diphotérine®. In fact, it is quite unusual for such serious burns to heal, and in extremely serious cases, the healing is generally associated with sequelae and obtained with more or less serious surgical operations. The interest of the rinsing with Diphotérine® was proved by in vitro and in vivo experiments which showed a return to a physiological pH a few minutes after its use. Diphotérine® is an amphoteric solution, hypertonic to the anterior chamber of the eye. So, Diphotérine® can chelate both acids and bases and, thanks to its hypertonicity, it can create a flow of water from the hypotonic anterior chamber to the external surface of the hypertonic cornea. This flow of liquid induces the outflow of the H<sup>+</sup> and OH<sup>-</sup> ions. But on an experimental in vivo point of view, the return to a physiological pH, which is a proof of the ocular extraction of the chemical product, exists only if the rinsing is made in the first minutes following the chemical splash. Our experimental study showed interesting anatomopathological results : the presence of a stromal oedema in the experiments without rinsing or with a rinsing by a 0.9% saline solution is quite remarkable as no oedema was observed with the rinsing with Diphotérine®. We can note that for our patient, the corneal oedema decreased after the rinsing with Diphotérine®.

The stromal oedema is a pejorative factor as Kubota and Fagerholm showed that the importance of this initial oedema is correlated to the importance of the leucoma, responsible for the decrease of the visual acuity. These authors explain that the stroma blank, thus created by the oedema, will be colonized by keratocytes. These ones will then form an anarchic net of collagen fibers which are responsible for the decrease of the transparency of the cornea. After the decrease of the amount of the chemical product in the eye, the second important factor in the treatment of a chemical burn is the fight against the stromal invasion due to the inflammatory cells. Thus, we must know that stromal invasion due to neutrophilic polynuclears was experimentally observed 2 hours after the chemical splash, with two peaks : the first peak happened 12 to 24 hours while the second peak nearly happened around day 21 with a beginning on day 12. This is the reason why we used strong doses of dexamethasone in order to continue to fight against the stromal oedema, that is why corticoids are interesting, even if used at a certain distance from the burn, as showed in our case. The other factor depends on the limbal stem cells and particularly on the density of the stem cells which stay by unit of corneal circumference. So the recurrent inferior nasal ulcer of our case can be explained by the fact that the burn, more serious on this level, induced the necrosis of the most important part of these limbal stem cells. the wound healing of this area will happen with a moderated conjunctivalization.



**Figure 2:** Final examination of the right eye: Total re-epithelialization of the cornea; stable neovascularization in the infero-nasal region; visual acuity: 14/20.

**CONCLUSION :** Our clinical case demonstrates that a well-conducted therapeutical protocol can sometimes heal the serious ocular chemical burns. Nevertheless, the prognostic of such burns remains dependent on the delay of the intervention and more particularly on the rapidity of the external ocular rinsing. Among the different rinsing solutions available, Diphotérine® seems none the less to hold an interesting position, even after a delay exceeding 10 minutes.

## REFERENCES

1. Tseng SCG, Tsai JF. Limbal transplantation for ocular surface reconstruction. A review. Fortschr Ophthalmol 1991;88, 236-42.
2. Gérard M, Louis V, Merle H, Josset P, Menerath JM, Blomet J. Etude expérimentale sur la pénétration intra-oculaire de l'ammoniaque. J Fr Ophtalmol 1999; 22, 10, 1047-1053
3. Gérard M, Josset P, Louis V, Menerath JM, Blomet J. Existe-t-il un délai pour le lavage oculaire externe dans le traitement d'une brûlure oculaire par l'ammoniaque? Comparaison de deux solutions de lavage : sérum physiologique et Diphotérine®. J Fr Ophtalmol 2000; 23, 5, 449-458.
4. Kubota M Fagerholm P. Corneal alkali burn in the rabbit. Waterbalance, healing and transparency. Acta Ophthalmol 1991; 69, 635-640.
5. Paterson CA, Williams RN, Parker AV. Characteristics of polymorphonuclear leukocyte infiltration into the alkali burned eye and the influence of sodium citrate. Exp Eye Res 1984; 39, 39, 701-708