



Emerg Med Clin N Am  
26 (2008) 17–34

EMERGENCY  
MEDICINE  
CLINICS OF  
NORTH AMERICA

## Ophthalmologic Procedures in the Emergency Department

Matthew R. Babineau, MD\*,  
Leon D. Sanchez, MD, MPH

*Department of Emergency Medicine, Beth Israel Deaconess Medical Center, One Deaconess  
Road, West Campus Clinical Center, 2nd Floor, Boston, MA 02215, USA*

Ophthalmologic emergencies account for up to 3% of visits to emergency departments in the United States [1]. Although isolated ocular complaints are rarely life-threatening, they can lead to significant short- and long-term morbidity, including permanent visual loss. The role of the emergency physician in management of ocular emergencies is similar to that for other chief complaints: (1) recognize and diagnose emergency conditions, (2) provide appropriate initial therapy, and (3) ensure correct disposition. This article reviews several of the essential ophthalmologic procedures that are within the scope of emergency medical practice.

### Visual acuity testing

A simple but vital part of the ophthalmologic examination is a test of visual acuity. This is essential for all patients who have ocular or visual complaints. The affected and non-affected eyes should be tested individually, and then together, using a Snellen chart or equivalent. If the patient wears corrective lenses during the examination (or is not wearing lenses that are usually used), this should be noted. A critical part of the visual acuity examination is that decreased visual acuity should be rechecked using a pinhole card. A pinhole corrects for most refractive errors, by ensuring that only light striking the lens perpendicularly reaches the retina. Initially abnormal visual acuity that corrects with a pinhole indicates a problem with the lens, and is less concerning to an emergency physician. If this does not correct the visual problems, it indicates pathology that is more likely located within the retina or central nervous system.

\* Corresponding author.

*E-mail address:* mbabinea@bidmc.harvard.edu (M.R. Babineau).

### Slit lamp examination

Along with visual acuity, pupillary movements, extra-ocular muscle movements, and funduscopy (all reviewed elsewhere in this issue), the slit lamp examination is an essential aspect of a complete ophthalmologic examination [2]. The slit lamp is an illuminated biomicroscope that allows a magnified, stereoscopic view of the eye and surrounding structures [2]. It is especially useful for evaluation of the anterior segment of the eye, and should be a standard part of the examination in all ophthalmologic complaints [3].

Despite some manufacturer-specific differences in slit lamps, some general principles apply to the use of this device. Each unit has an illumination system and an observation system. The illumination system is a light source that projects through the slit aperture and onto the patient's eyes. This part should be mobile to allow different angles of light projection. Most systems have a rheostat mechanism that allows the examiner to change the shape and size of the slit beam, as well as a means to change the filter on the beam (neutral, cobalt blue, and red-free) [4]. The observation system is a binocular microscope, which typically allows magnification from 6X to 40X. The observation system is mounted on a chassis, which can be moved horizontally with a joystick device. Often the handle of the joystick can be rotated to allow for vertical movement of the observation system.

To perform the examination, the patient is asked to place his chin on the chin rest, with the forehead resting on the forehead bar. Efforts should be maintained to ensure that the patient is in a comfortable position, because this will lead to a more efficient examination [5]. The chin rest is adjusted so that the patient's eyes rest at the level of the black marker on the vertical pole next to the patient's face [3]. The height of the slit lamp is adjusted so that the slit beam is centered on the patient's eyes. The patient should be asked to fix his gaze on a specific location (such as the examiner's ear) [5].

Initially, the examiner should adjust the diopter rings on the ocular piece to account for his or her individual refractive error and accommodation [6]. This will also account for any misalignment in the instrument [6]. This is done by using the focusing rod on the instrument [7]. The slit beam should be set on a low-voltage, wide beam, and should be at 45° from the patient-clinician axis [4]. The microscope should be set at its lowest magnification, and the joystick is used to move the device on the chassis until the eye is in focus. Once the eye is in focus, the clinician begins a systematic examination of individual structures. Although any system may work, the authors recommend using the mnemonic L-L-L-L-L-C-C-C (Table 1). If any abnormality is detected, the beam should be narrowed to help assess the depth, extent, and level of the abnormality. At this time, the magnification can also be increased for further evaluation.

Assessment of the anterior chamber (the region between the cornea and iris) is perhaps the most difficult part of the examination. The purpose of the

Table 1

Mnemonic for systematically assessing all portions of the eye, eyelid and adnexae during routine slit lamp examination

	Stands for	Example of pathology
L	Lids (eyelids)	Lacerations, edema, meibomian cyst
L	Lashes (eyelashes)	Discharge, inverted eye lash
L	Lacrima	Discharge, plugging, cannalicular lacerations
L	Lens (and iris)	Opacification/cataract, dislodgement, pupil shape and function, synechia, iridodialysis, blood vessels
L	Limbus	Injection
C	Conjunctiva (and sclera)	Hyperemia, follicles, chemosis, foreign body
C	Cornea (and iris)	Edema, foreign body, abrasions, ulcers, opacification, keratitic precipitates
C	Chamber (anterior)	Cells/flare, hyphema/hypopyon, shallow chamber

anterior chamber examination is mainly to assess the depth of the chamber (narrow in acute closed angle glaucoma), and to assess for the presence of "cells and flare" (present in inflammatory conditions such as uveitis).

To assess anterior chamber angle depth, use low magnification and a narrow slit beam at 60° from the patient-clinician axis [8]. The beam is centered as close to the limbus as possible, and normal to the cornea [4]. The depth is assessed by comparing the width of the cornea as seen by the light beam with the depth of the aqueous, which is represented by the darker section between the iris and the posterior aspect of the cornea [4]. An aqueous-to-cornea ratio of smaller than 1:4 (eg, a thin dark section compared with the corneal thickness) indicates a dangerously narrow angle, whereas a ratio of greater than 1:2 indicates an open angle [4]. To assess for cells and flare, the slit beam should be between 45° and 60°, and focused onto the front of the cornea. The examiner should assess the space between the focused beam of light (on the cornea), and the more diffuse light (on the lens), using the pupil as a dark background. In normal patients, this area should be completely clear. "Flare" appears as scattered light, and is caused by the presence of inflammatory proteins in the aqueous humor; cells appear as small, floating particulate matter within the aqueous (Fig. 1) [3].

#### Flourescein examination

The flourescein examination is another important aspect of a complete ophthalmologic examination. It is used to detect defects in the corneal epithelium [3,9]. It should be done in all evaluations of ocular trauma, foreign body, or suspected infection (including conjunctivitis, because symptoms of herpetic keratitis can occasionally mimic conjunctivitis) [10]. The only absolute contraindication to the procedure is a flourescein allergy.

Sodium flourescein is a water-soluble dye that flouresces in an alkaline environment (such as that encountered below the corneal epithelium), and




Fig. 1. Positioning for examination of the anterior chamber. Note the following: forehead is resting on the forehead bar; the patient's eyes rest at the level of the black marker on the vertical pole next to the patient's face; two strips of light are visible, one at the cornea, the second at the iris with a clear anterior chamber.

not in the acidic environment (such as the tear film) [10]. Therefore, when instilled into the eye, defects in the corneal epithelium will show up as bright green when viewed under a blue light (on the slit lamp, or with a Wood's lamp). Deep corneal defects may allow penetration of fluorescein into the anterior chamber. Although this is not a contraindication to the examination (the substance is nontoxic), it may cause a "flare" appearance on examination of the anterior chamber [10].

To perform the fluorescein examination, a blue light source is first passed over the eye. Certain infectious organisms (eg, some species of *Pseudomonas* bacteria) may fluoresce under a blue light even without fluorescein. Then an individually wrapped fluorescein paper is moistened with sterile water or the patient's own tear film. Many practitioners use topical anesthetic to wet the strip. This is not recommended by some authors, because the anesthetic solution may cause some patients to develop a superficial punctate keratitis, thereby confounding the examination [10]; however, in patients who have significant pain or blepharospasm and are refusing to open the eye, the use of topical anesthetic is advised [10]. The strip is then touched to the tear well, and removed. The patient is asked to blink several times to distribute the dye in a thin film over the entire surface of the eye. Too much dye can impair the examination by causing the eye to become flooded with fluorescein. The eye is then inspected with a blue light source, and areas of green fluorescence, indicating corneal disruption, are noted [9].

A variation of this standard fluorescein examination, the Seidel test, is used to test for a globe injury or full-thickness corneal disruption. To perform the test, a large amount of fluorescein is instilled into the eye (preferably over the area of suspected perforation), which makes the eye appear orange. The globe is then examined for a dark stream interrupting the fluorescein, indicating leakage of aqueous humor, and suggesting the diagnosis of globe rupture [10,11].

Note that in the past, bottles containing fluorescein dye were used directly to instill the solution into the eye, but this practice is now discouraged because of the possibility of these solutions becoming contaminated with bacterial flora, particularly *Pseudomonas* [9,10].

### Tonometry

Tonometry is the determination of intraocular pressure (IOP). Elevated intraocular pressures are associated with vision loss. The main indications of the procedure are to confirm a clinical diagnosis of acute angle closure glaucoma and to determine a baseline IOP after a blunt eye injury [10]. It can also be used to determine baseline IOPs in patients who have conditions such as iritis, or risk factors for open angle glaucoma [10].

With any method of tonometry, an intraocular pressure of 12 to 20 mmHg is considered normal. With an intraocular pressure of greater than 30 mmHg, especially in the context of abnormal optic disks or with visual field defects, therapy for glaucoma should be promptly initiated, and ophthalmologic consultation is warranted. IOPs between 20 and 30 mmHg require urgent follow-up with ophthalmology [9].

Tonometry should be avoided in suspected penetrating eye injuries, because it can worsen the defect and lead to extrusion of intraocular contents. Other relative contraindications to tonometry include eye infection (unless using a sterile cover), patients who have corneal defects, or patients who cannot remain relaxed and may induce corneal injury with sudden, rapid movements [9,10]. Corneal abrasions are rarely caused by tonometry [9].

There are several distinct methods of tonometry. The simplest is direct palpation of the globe. In this method, patients are instructed to look downward, but keep the eyes open. The clinician's index finger is used to gently palpate the globe through the eyelid, with just enough pressure applied to indent the globe slightly. This procedure is repeated on the unaffected eye as well, and the examiner qualitatively compares the amount of pressure required to indent each eye [10]. One study, comparing digital palpation with Goldmann tonometry, found digital palpation to be insensitive, accurately identifying only five of seven eyes that had an IOP greater than 30 mmHg [12]. In clinical practice, it may be more useful as a quick screening tool to test for asymmetric intraocular pressures between the two eyes.

Impression tonometry is the most common method used in most emergency departments. Impression tonometry measures intraocular pressure by measuring the amount of corneal indentation produced by a certain amount of force [13]. The two types of impression tonometry typically used by emergency physicians are Schiottz tonometry and a portable handheld instrument that provides readings that correlate closely with Goldmann tonometry.

With Schiottz tonometry, the first step is to ensure that the tonometer is functioning properly. Most Schiottz tonometers come with a metal test

button in the kit. The tonometer can be lowered onto the test button to verify that the plunger is freely mobile with various amounts of pressure. If not, it can lead to falsely low readings, and should be cleaned with an alcohol solution [9]. To begin, the patient is placed in a supine position and asked to gaze straight ahead at a distant object. Topical anesthetic is instilled into the eyes. The clinician then separates the eyelids, taking care to avoid exerting manual pressure on the globe while doing so (this could lead to a falsely elevated reading). The tonometer is held in the patient's line of sight, and the patient is instructed that the procedure will not be painful (anxiety can cause tension in extra-ocular muscles and elevate the IOP) [10]. The tonometer foot is lowered onto the cornea, held loosely between the examiner's index finger and thumb. With the tonometer vertical, the clinician reads the number from the scale on the top of the tonometer. If the reading is low ( $<4$  or  $<5$ ), additional weight should be added to the scale and the above procedure repeated [9]. The reading is compared with a conversion table (based on the scale weight), thus yielding an intraocular pressure reading. This is compared between both eyes.

The other type of impression tonometry frequently used in the emergency department is the handheld digital device, which is used in a similar fashion to the Schiotz tonometer. Although somewhat less accurate, especially at high IOPs, its measurements have good interexaminer reliability, and it can be used with the patient in any position [10]. The pen must be calibrated at least once per day (see package insert for instructions on calibration). To use the device, the eye is instilled with topical anesthetic, and the patient is asked to relax and maintain his gaze fixed on a distant object. A fresh latex cover is placed over the end of the pen. The device is held in the same manner as a pen, and touched lightly four times to the cornea at a perpendicular angle. With each touch, the probe records an IOP. After the fourth touch, a final beep sounds and the liquid crystal display (LCD) screen displays the average IOP measurement in mmHg, along with a series of dashes. The dashes correspond to the statistical variance of the four measurements (with more dashes indicated a higher variance between the individual measurements). A single dash indicates that all measurements were within 20% of each other. If four dashes appear, it indicates that too few valid readings were obtained, and the process should be repeated [10]. The probe may need to be recalibrated if this problem continues.

Applanation tonometry is a very accurate method of tonometry that is less frequently used in the emergency department setting. This device is typically found attached to the slit lamp, and is performed as a part of the slit lamp examination. The patient is arranged in the slit lamp apparatus as described previously, and topical anesthesia and fluorescein dye are instilled. The cobalt blue filter is selected and the aperture set so the beam is fully open (as would be done for an evaluation of corneal abrasion) [10]. The illumination apparatus is angled at  $45^\circ$  to  $60^\circ$ , and directed such that it shines through the applanation prism. The pressure knob of the tonometer

is turned to its lowest setting (10 mmHg), so that when corneal contact is placed, there will be only light pressure. The instrument is brought toward the patient's eye with the joystick control. Once contact is made with the cornea, a diffuse bluish glow will be visible throughout the limbus. When the operator looks through the ocular pieces, he will see two blue semicircles bordered by an arc of green light [10]. The semicircles may pulse in synchrony with the patient's heartbeat. The pressure knob is adjusted such that the ends of the semicircles are in contact and aligned. If they overlap it indicates the tonometer pressure is too high. If they are not in contact, it indicates that the pressure is too low (Fig. 2) [10].

There are several sources of error with applanation tonometry. Accommodation, Valsalva maneuver, and vertical gaze can cause large errors in readings [14]. Furthermore, repeated measurements can cause a false underestimation of intraocular pressure. Other sources of error are similar to those in the above-described methods, with the important exception that ocular rigidity does not affect the measurements [10].

Other methods of tonometry, such as the McKay-Marg method and pneumatic tonometry, are less frequently used, and discussion of these methods can be found elsewhere in this issue.

### Lid eversion

Lid eversion is a simple but essential task for the emergency practitioner to be familiar with. It is useful primarily for inspecting the tarsal conjunctiva and fornices, as well as to localize a foreign body located in one of these areas.

To evert the upper lid, the patient is instructed to look downwards. The clinician grasps the eyelids at the lid margin with the thumb and index finger. The upper lid is gently pulled downward and outward, and a cotton-tipped applicator is used to press on the superior aspect of the tarsal plate, over the lid. The examiner then turns this lid rapidly outward and upward over the cotton swab. The lashes can be held against the superior orbital rim to keep the lid everted while the adnexal structures are inspected [10]. To return the lid to normal position, the examiner releases his grip on the lid margin, and the patient is simply instructed to look upward [9].

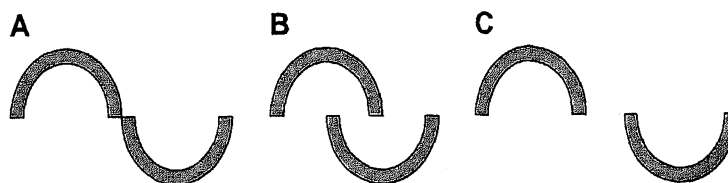


Fig. 2. Schematic representation of visualized semicircles while using applanation tonometer. (A) Alignment indicating correct pressure reading. (B) Pressure reading is too high. (C) Pressure reading is too low.

The lower eyelid is smaller, and lacks a tarsal plate, and therefore is not suitable to eversion; however, full inspection of the fornices and deep adnexae can be readily accomplished via directly pulling at the base of the eyelid.

### Foreign body removal

Ocular foreign bodies represent a high-risk chief complaint because they can be vision-threatening in both the short and long term. The two tasks that face the emergency clinician in this situation are: (1) to determine if the foreign body is superficial or intraocular, and (2) to remove superficial foreign bodies.

Intraocular foreign bodies (IOFBs) are diagnosed through a variety of modalities. First, gross inspection is performed, looking for features that suggest perforation, such as prolapse of intraocular contents, changes in pupillary anatomy, or conjunctival edema [15]. Lid eversion is performed to assess for forniceal foreign bodies. The slit lamp examination may reveal a foreign body in the anterior chamber (~15% of IOFBs) [15], and the entire surface of the eye should be inspected, with and without fluorescein [10]. Posterior foreign bodies are more difficult for the emergency physician to assess by direct visualization; however, this may be the only opportunity to do so before the foreign body is obscured by vitreal hemorrhage or cataract formation [15]. The practice of pupillary dilation is currently controversial; although it is helpful in determining location of IOFBs, it may compound problems (ie, if it pulls out iris that is plugging a corneal laceration) [15].

If an IOFB is suspected based on the examination, ophthalmology should be consulted immediately. The priority of the emergency provider is then to prevent further globe injury. The patient should be kept quiet, with the head of the bed elevated, and a shield should be placed over the eye (taking care to make sure pressure points are directed onto the orbits, and not the globe). Tonometry or other procedures that place pressure on the eye should be avoided [10]. In these patients, systemic antibiotics should be given, as should antiemetics (to prevent increased intraocular pressures from vomiting) [15].

When the initial ophthalmologic examination is complete, further imaging is often necessary. It is important that the emergency provider does not stop the evaluation after a corneal foreign body or single IOFB is discovered, or he may overlook the presence of multiple foreign bodies. Historically, plain radiographs (anteroposterior and lateral orbital views) have been used to look for radiopaque foreign bodies, with precise localization performed by using various radiographic markers (ie, Comberg's method or Sweet's method) [15]. Both of these have been shown to have significant inaccuracy, and to miss radiolucent or small foreign bodies. Ultrasonography (US) is an increasingly popular modality, because of its immediate availability for emergency physicians familiar with the practice (see below



for a complete discussion of this topic). At present, CT scans are considered the gold standard, and have the highest accuracy in diagnosis and localization [16]. The physician should request 3 mm sections through the orbit, unless a foreign body was seen on plain radiography, in which case 6 mm sections are acceptable [17]. MRI is not considered a first-line diagnostic modality, because it is contraindicated in the case of known or suspected metallic IOFB (70%–90% of cases) [15], and is typically more difficult to obtain than the other studies mentioned above.

If a foreign body has been found to penetrate the globe through using any of these modalities, emergent ophthalmologic consultation is indicated. The emergency physician should take care to note visual acuity, lens damage, presence of vitreal hemorrhage, type of IOFB, and entry site, because these are shown to be the most important indicators of final visual outcome [18].

If an uncomplicated (ie, not intraocular, multiple, or deeply embedded) ocular foreign body is discovered, the emergency physician should attempt to remove it. The exception is when the patient is uncooperative, in which case ophthalmology should be consulted to remove it [10].

To remove the foreign body, the eye is anesthetized with topical anesthetic, and a slit lamp examination is performed. The patient is asked to move the eye to a position such that the foreign body is rotated to the highest point of the cornea [9]. Successful removal can often be achieved by gentle jet stream irrigation [10], which may be especially useful if there is more than one foreign body [11]. Another method is to use a cotton-tipped applicator that has been moistened with topical anesthetic [15]. This can be rolled over the foreign body to gently lift the object off of the ocular surface. If these less invasive methods are unsuccessful, needle removal is often required. A 25-gauge needle is placed on a tuberculin syringe. The foreign body is approached tangentially to the globe (viewed through the slit lamp), and the beveled edge is used to gently scrape it off of the cornea [15]. Although this procedure may inspire some degree of anxiety in both the clinician and the patient, the corneal epithelium is resilient and should not be perforated with careful manipulation. Many practitioners now recommend avoidance of the “spud” device, because there may be a risk of increased corneal scarring [9,15].

Multiple corneal foreign bodies can be removed with the same methods, though may be more amenable to jet stream irrigation [11]. If there are diffusely located foreign bodies (ie, from an explosion), however, the patient should be referred to ophthalmology, where most of the corneal epithelium will be removed to decrease the scarring. Another special situation involves rust rings. These can often be removed with a needle (as described above) or with a pressure sensitive drill, but are not a true emergency [10]. Many will wash out spontaneously, and the others can be referred nonemergently to ophthalmology for removal [15]. During the next 24 to 48 hours after formation, the iron will often necrose the surrounding epithelial cells and allow the ring to then be removed intact [10]. Delayed removal may be especially

indicated in the case of a rust ring that is deep or located in the center of the visual field, because this may allow time for the rust to migrate to the corneal surface, thus facilitating extraction [11].

Once the foreign body has been removed, the eye should be irrigated profusely. Studies have shown a lack of consensus among providers regarding further management of these injuries [19]. Topical nonsteroidal anti-inflammatory drugs (NSAIDs) have been shown to provide effective analgesia in several randomized clinical trials [20,21], and should be prescribed, with or without systemic analgesics (NSAID or opioid). Some authors recommend using a cycloplegic for pain caused by ciliary spasm, although this practice is not routine [11,15,19,22]. Artificial tears may help with superficial irritation [11]. Topical antibiotics and a tetanus booster may be given, although both of these practices are controversial with superficial injuries [9,10,23]. One prospective study where removed corneal foreign bodies were cultured showed that 32.7% grew positive cultures, mostly staphylococcal and streptococcal species [24]. *Pseudomonas* species are more common in patients who wear contact lenses [25], therefore mandating treatment with a quinolone antibiotic. Patching is not generally recommended, because studies have shown no significant improvement in patient comfort or healing rate [26,27]. Topical steroids should be avoided, because they may promote fungal ulceration. Topical anesthetics should also be avoided, because these agents may hide pain associated with retained foreign body or corneal ulceration [28].

Patients who have only superficial injuries do not need ophthalmology follow-up unless symptoms persist [10]. Patients who have large or central defects, purulent discharge, or anterior chamber reactions, but without globe penetration, can be discharged with 24-hour follow-up with ophthalmology for repeat examination and evaluation of infection [9,11].

### Contact lens removal

The removal of contact lenses is a simple procedure that emergency physicians should be comfortable with. The patient should be asked whether he wears "soft" or "hard" lenses, because this may affect the method of removal. The first task is to localize the contact lens. Often the patient may not be able to sense the lens if it is in a conjunctival fornix. The patient is examined in the standard fashion. The upper lid is everted. If the patient has significant pain or blepharospasm, the eye should be topically anesthetized. Note that fluorescein dye can be used to help localize the lens, although it will permanently stain a soft lens.

When the lens is encountered, gentle pressure should be applied with a cotton-tipped applicator or a gloved finger [29]. If it is loose, it may be slid over the cornea, and the patient can remove it as usual [29]. A soft lens can be safely removed from any part of the eye. If the lens is somewhat adherent, gentle irrigation with a plastic catheter may moisten it and allow it

to be moved to a position where it can be easily removed from the eye [30]. If it continues to be adherent, the practitioner should attempt to remove the lens directly by gently compressing it between a gloved thumb and forefinger to break the suction with the globe, then remove it.

If these steps fail, there are devices available that can help in removal. For soft lenses, rubber-tipped forceps can be used to squeeze the lens and allow removal [29]. For hard lenses, suction-cup removers can be used. The suction cup should be moistened with saline, and then applied gently directly to the front of the lens [30]. Once a seal is formed, the lens should be pulled off perpendicularly to the globe.

After removal, a fluorescein examination should be performed to evaluate for the presence of corneal abrasions. These should be treated as any other corneal abrasion, with the caveat that if topical antibiotics are prescribed, it should be a quinolone (rather than a macrolide) to cover *Pseudomonas* and other organisms more common in contact-lens wearers [25,30]. The patient should be instructed not to wear the lens for at least 24 hours, or until free of any symptoms [29].

### Eye irrigation

The foundation of emergency treatment for chemical burns is immediate and copious irrigation, because this has been shown to have the greatest effect on visual prognosis [31].

There are two broad types of chemical burn: acid and alkali. Acid burns produce a coagulative necrosis, and therefore, after the initial injury, the deeper structures may be somewhat protected from further injury (with the notable exception of hydrofluoric acid burns). Alkali burns produce a liquefactive necrosis and penetrate more rapidly into the anterior chamber (within minutes) [32].

Despite these differences, the treatment of ocular chemical burns is the same. When a patient presents with an ocular burn, irrigation should begin immediately, even in triage [33], especially because in practice, immediate, on-site irrigation occurs only in 40% to 50% of patients [34]. Physical examination should initially be limited to, at most, a very rapid visual acuity measurement and the determination of pH [3].

Measurement of ocular surface pH is a simple task. One simply touches the end of a piece of pH litmus paper to the tear well and compares the resulting color to the color scale located on the side of the container that holds the strips. The shelf life of the strips is roughly 5 years according to the manufacturer. There are several methods of irrigating the eye. Eye showers are available at many workplaces, but the actual amount of irrigant they deliver to the corneal surface and conjunctival fornices may be limited by blepharospasm caused by pain. In the emergency department, the ideal device to use is a Morgan lens. The Morgan lens is a molded lens that is applied directly to the eye surface, and can be directly attached to a length

of intravenous (IV) tubing to allow continuous irrigation of the eye. To insert the lens, the patient should be instructed to look down, as the upper lid is grasped and the superior end of the lens is placed under the lid. This procedure is repeated with the lower lid. At this point, the lens is connected to the tubing from the irrigant, and the solution is allowed to bathe the eye. If the Morgan lens is not available, the eye can be directly irrigated with the cut end of IV tubing. This often requires an assistant to manually retract the eyelids throughout the procedure, however; otherwise, blepharospasm is likely to limit the amount of irrigant that reaches the corneal surface [15].

The irrigant is instilled until the pH of the eye returns to normal (pH 6.8–7.4) [9]. After irrigation, the practitioner should wait for 5 minutes before checking the pH, because earlier measurements may give a falsely reassuring pH by measuring the pH of the irrigant solution [11]. After achieving a normal pH, the eye should be continually irrigated for at least 30 more minutes [34]. Some authors recommend episodic irrigation for up to the following 24 hours [34].

There may be controversy regarding the specific type of irrigant to be used. Whereas different features make some solutions preferable to others, the most important factor is rapid institution of therapy, and it is essential to not delay irrigation while setting up the equipment or finding the best buffer solution [9]. Irrigation works by mechanical and chemical means. Mechanically, a volume of liquid coursing over the eye serves to remove any excess particles or drops of the offending agent. In this way, even tap water or other nonsterile fluid is a suitable irrigant if used immediately [11,34].

The preferred buffer solutions are amphoteric (universal) buffers that may help to limit further damage to the eye caused by exothermic chemical reactions between the irrigant and the offending agent [9]. Ethylenediaminetetraacetic acid (EDTA) used to be the primary amphoteric buffer, but has now been largely replaced by diphoterine [34,35]. Notably, acidic solutions should not be used to neutralize an alkaline burn, and alkaline solutions should not be used to neutralize an acidic burn [11]. Another consideration in use of buffers is the osmolarity. Because the cornea has a higher osmolarity (420 mOsm/L) than other areas in the human body, use of a hypotonic solution can lead to increased corneal water uptake, and therefore, exacerbate corneal edema from a burn [34,36]. This will also allow deeper corneal penetration of corrosive materials [34]. Therefore, osmotic solutions—normal saline (NS), lactated Ringer's solution (LR), or balanced salt solution (BSS)—are often preferred to nonosmotic solutions such as tap water. The pH of the solution is also a factor in the choice of irrigant. Normal saline has a pH of 4.5 to 7.0, lactated Ringer's is 6.2 to 7.5, and balanced salt solution is 7.1 to 7.4 [37]. For all of these reasons, many authors prefer BSS or LR as an irrigant, although isotonic NS is considered to be an appropriate substitute if others are unavailable [32], and even tap water irrigation has been shown to decrease the severity of ocular burns [36,38]. Each of these solutions has been shown to have equal tolerability to patients

[39], although warmed solutions have been shown to be better tolerated than room temperature [40].

Following adequate irrigation, it is important to do a complete ophthalmologic examination to rule out any retained foreign bodies, corneal injuries, or other injuries that need attention [9,11]. Some authors recommend sweeping the fornices with a moistened cotton-tipped applicator to remove any remaining particles of caustic material or necrotic conjunctiva. All patients, even those who have minor burns, should receive a tetanus shot, topical antibiotics, and oral analgesics, and be instructed to follow up with ophthalmology within 24 hours. Cycloplegics and pressure patches are controversial. For more severe burns, and especially those caused from alkali exposure, hospitalization may be warranted for intravenous antibiotics and further ophthalmologic care. In these cases, ophthalmologic consultation is required before institution of therapy such as cycloplegics, topical steroids, and further therapy. Prognosis depends on the depth of the injury, with opacification of the cornea and greater than 50% area of conjunctival ischemia being predictive of a poor outcome (Table 2).

### Paracentesis

Anterior chamber paracentesis is a rare procedure in the emergency department; however, it is one that emergency providers should feel comfortable performing. The primary indication in the emergency setting is in the treatment of central retinal artery occlusion. In this disease, there is acute embolization to the central retinal artery, which is manifested by a painless loss of vision in the affected eye, and appears as a pale optic disc or a cherry red spot on fundoscopy. Immediate treatment is indicated if the patient presents within 24 to 48 hours of symptom onset, because once the retina has infarcted, vision loss is permanent [13]. Even with appropriate treatment, successful return of full visual acuity is rare [13].

Initial treatment is directed at improving retinal blood flow and trying to dislodge the clot into a more distal branch of the retinal artery. Common maneuvers include supine positioning (which improves retinal blood flow),

Table 2  
Classification and prognosis of chemical ocular burns

Grade	Corneal findings	Conjunctival ischemia	Prognosis
I	Only epithelial loss.	None	Very good
II	Some edema and haze.	<1/3 of limbus	Some permanent scarring may occur.
III	Significant haziness	<1/2 limbus	Variable, usually some visual impairment
IV	Opaque	>1/2 limbus	Poor

Data from Cheh AI, Reensta-Buras WR. Ocular. <http://www.emedicine.com/emerg/topic736.htm>. Accessed August 3, 2007.

digital orbital massage (to diminish intraocular pressure and possibly dislodge the clot), and intravenous acetazolamide or topical B-blockers to further decrease intraocular pressure [41]. Carbogen therapy involves inhalation of a 5% CO<sub>2</sub>/95% O<sub>2</sub> mixture of gas. The carbon dioxide may dilate retinal arterioles, thereby enhancing the delivery of oxygen-rich blood to the ischemic retina [42]. This should be done for 10 minutes every 2 hours, and continued for 48 hours. Hyperbaric oxygen therapy may provide similar benefits, but must be initiated soon after symptom onset (within 12 hours, and preferably within 2 hours) [42]. If these techniques fail to restore vision or are unavailable, however, anterior chamber paracentesis should be attempted.

To perform the procedure, the eye is topically anesthetized. The provider prepares a 30-gauge needle on a tuberculin syringe. The patient is positioned in the slit lamp apparatus as described above. The anterior chamber is carefully entered at the limbus, with the bevel facing the examiner. The clinician then removes 0.1 to 0.2 cc of aqueous, until the chamber becomes slightly shallower. The needle is withdrawn and the patient should then be given a topical antibiotic [41].

### **Lateral canthotomy**

Lateral canthotomy is another rarely indicated but potentially vision-sparing procedure that emergency practitioners must be familiar with. The purpose of the procedure is to emergently relieve retro-orbital pressure after trauma. With significant retrobulbar hemorrhage, the optic nerve can become ischemic, leading to permanent visual loss within 90 to 120 minutes of ischemic time [43]. Although retrobulbar hemorrhage is now often diagnosed based on CT scan findings in the trauma victim, signs of retrobulbar hemorrhage include acute loss of visual acuity, elevated IOP (>40 mm Hg), and proptosis [43]. There are other more subtle findings suggestive of the diagnosis, including afferent pupillary defect, optic nerve pallor, and severe eye pain [43], but these findings alone should not merit canthotomy without confirmatory findings.

To perform the procedure, the patient is placed in the supine position, and 1 to 2 cc of 1% lidocaine with epinephrine is injected into the lateral canthus. The eye is then irrigated with normal saline to ensure a clean, noncontaminated working surface. A straight Kelly clamp is used to crimp the skin at the lateral canthus, then promptly removed. This serves two functions: it helps with hemostasis, and it marks the location for the canthotomy. At this point, an assistant may be useful to laterally retract the lid, thereby reducing the risk of inadvertent globe injury. Small scissors are used to make a 1 to 2 cm lateral incision along the line formed by the crimped Kelly clamp. The lower eyelid is then retracted to exposure the lateral canthus tendon, which can then be cut with the scissors. A small amount of blood should be expressed at this time. The intraocular pressure should be less than 40 mm Hg if the procedure is successful, and the patient

should have improved visual acuity. If the pressure continues to remain elevated, the superior canthus can be cut in the same way [43].

### Ocular ultrasonography

Bedside US, performed by emergency physicians, is a procedure that is gaining popularity in the emergency department. It can be a rapid, safe, and noninvasive method to make several diagnoses, and may be especially useful in the trauma patient where periorbital swelling limits direct visualization of the eye and surrounding structures [1]. It is also useful in nontraumatic eye complaints, because patients who have new-onset visual loss can be rapidly evaluated for retinal detachment or central retinal artery or vein occlusion (Table 3) [1].

To perform ocular US, a linear 10-mHz transducer (also known as a "vascular" probe) is used. The power output and gain settings should be minimized, because this decreases artifact from eyelid echoes and allows better visualization of ocular structures [44]. The patient is asked to close his eyes, and ultrasound gel is applied to the closed eye. The clinician should take care to avoid putting excessive pressure on the globe while performing the scan, and if there is a possibility of globe rupture, the scan should be performed without the transducer touching the eyelid (instead using a larger amount of ultrasound gel) [44]. The scan is done in both sagittal and transverse planes, as well as with two-dimensional Doppler imaging if there is suspicion of central retinal artery or vein occlusion [1,44]. The imaging can typically be done by an experienced sonographer within 60 to 90 seconds [1].

There are few prospective studies regarding the role of ocular US in the emergency department. In one study by Blaivas and colleagues [1], 61 consecutive patients who had ocular complaints were enrolled, all of whom had bedside ocular US followed by a "confirmatory" study (either CT of orbits or formal ophthalmologic examination). The scans were done by experienced attending physicians or residents who had undergone a 1-hour lecture

Table 3  
Ocular pathology visible with ultrasonography, and sonographic findings

Pathology	Ultrasonographic appearance
Retinal detachment	Band of echogenic material within vitreous body
Vitreous detachment	Collection of echogenic material between vitreous body and retina
Vitreous hemorrhage	Echogenic material within vitreous body
Retrobulbar hemorrhage	Hypoechoic lucency deep to retina
Lens dislocation	Lens in abnormal position within globe
Globe rupture	Difference in globe size between eyes; scleral folds
Intraocular foreign body	Echogenic foreign body visualized within globe
Central retinal artery/vein occlusion	Absence of Doppler flow at posterior retina

*Data from* Legome E, Pancu D. Future applications for emergency ultrasound. *Emerg Med Clin N Am* 2004;22:817-27.

and a 1-hour hands-on teaching experience. Of these 61 patients, the correct diagnosis was made by bedside US in 60, yielding test characteristics of: sensitivity 100% (95% CI 94–100), specificity 97% (95% CI 88–99), positive predictive value (PPV) 96% (95% CI 88–99), negative predictive value (NPV) 100% (95% CI 94–100) [1]. There have been no studies that look at how bedside ocular US changes decision-making regarding treatment, further diagnostic studies, or disposition [1,44].

Another novel use of bedside ocular US is in the evaluation of the optic nerve sheath diameter (ONSD) in a patient who has possible increased intracranial pressure (ICP). The scan is performed as above, and the ONSD is measured in each eye at a distance of 3 mm behind the globe. The ONSD measurement is then an average of both eyes [45]. An increased ONSD (> 5.0 mm in adults, > 4.5 mm in children age 1–15 years, or > 4.0 mm in children less than 1 year old) is considered abnormal and indicative of elevated intracranial pressure [45–47]. One study [46] has shown abnormal ONSD to have a 100% sensitivity (95% CI 68–100) for CT findings consistent with increased ICP, and a specificity of 63% (95% CI 50–76). Furthermore, this had a sensitivity of 84% and specificity of 73% for any traumatic intracranial injury [46].

### Summary

Ophthalmologic complaints are a small but important proportion of emergency department visits. Familiarity with many important ophthalmologic procedures is an essential part of any emergency clinician's armamentarium, and may help to decrease morbidity associated with ophthalmologic emergencies.

### References

- [1] Blaivas M, Theodoro D, Sierzenski PR. A study of bedside ocular ultrasonography in the emergency department. *Acad Emerg Med* 2002;9(8):791–9.
- [2] Kercheval DB, Terry JE. Essentials of slit lamp biomicroscopy. *J Am Optom Assoc* 1997; 48(11):1383–9.
- [3] Broocker G. Chapter 15: the ophthalmic examination. In: Wolfson AB, Hendey GW, Hendry PL, et al, editors. *Harwood-Nuss' clinical practice of emergency medicine*. 4th edition. Philadelphia: Lippincott, Williams and Wilkins; 2005. p. 112–7.
- [4] Available at: <http://www.academy.org.uk/lectures/eperjesi5.htm>. Accessed August 2, 2007.
- [5] Nemeth SC. Basic slit lamp techniques. *J Ophthalmic Nurs Technol* 1996;15(4):134–41.
- [6] Blumenthal EZ, Serpetopolous CN. On focusing the slit lamp: part I. an inaccurate ocular setting—what is there to lose? *Surv Ophthalmol* 1998;42(4):351–4.
- [7] Blumenthal EZ, Serpetopolous CN. On focusing the slit lamp: part II. “The fading-slit test”—verifying the ocular setting. *Surv Ophthalmol* 1998;42(4):355–7.
- [8] Osuobeni EP, Oduwaiye KA. The effect of illumination-microscope angle on slit lamp estimate of the anterior chamber depth. *Optom Vis Sci* 2003;80(3):237–44.



- [9] Dennis WR Jr, Dennis AM. Chapter 31: Eye emergencies. In: Stone CK, Humphries EH, editors. *Current emergency diagnosis and treatment*. 5th edition. Lange Medical Books/McGraw-Hill; 2004.
- [10] Knoop KJ, Dennis WR, Hedges JR. Ophthalmologic procedures. In: Roberts MD, Hedges JR, editors. *Clinical procedures in emergency medicine*. 4th edition.
- [11] Cullom Jr RD, Chang B, editors. *The Wills eye manual: office and emergency room diagnosis and treatment of eye disease*. 2nd edition. 1994.
- [12] Baum J, Chaturvedi N, Netland PA, et al. Assessment of intraocular pressure by palpation. *Am J Ophthalmol* 1995;119(5):650-1.
- [13] Beers MH, Porter RS, Jones, TV, et al, editors. *The Merck manual of diagnosis and therapy—chapter 98: Approach to the ophthalmologic patient*. 18th edition. 2006.
- [14] Whitacre MM, Stein R. Sources of error with use of Goldmann-type tonometers. *Surv Ophthalmol* 1993;38(1):1-30.
- [15] Schwartz GR, et al. Ocular foreign body removal. In: *Principles & practice of emergency medicine*. 4th edition. Copyright (c) 1999 Lippincott Williams & Wilkins.
- [16] Coleman DJ, Lucas BC, Rondeau MJ, et al. Management of intraocular foreign bodies. *Ophthalmology* 1987;94:1647-53.
- [17] Etherington RJ, Hourihan MD. Localisation of intraocular and intraorbital foreign bodies using computerized tomography. *Clin Radiol* 1989;40:610-4.
- [18] De Juan E Jr, Sternberg P Jr, Michels RG. Penetrating ocular injuries: types of injuries and visual results. *Ophthalmology* 1983;90:1318-22.
- [19] Calder L, Baladubramanian S, Stiell I. Lack of consensus on corneal abrasion management: results of a national survey. *CJEM* 2004;6(6):402-7.
- [20] Donnenfeld ED, Selkin BA, Perry HD, et al. Controlled evaluation of a bandage contact lens and a topical non-steroidal anti-inflammatory drug in treating corneal abrasions. *Ophthalmology* 1995;102:979-84.
- [21] Weaver CS, Terrell KM. Evidence-based emergency medicine. Update: do ophthalmic non-steroidal anti-inflammatory drugs reduce the pain associated with simple corneal abrasion without delaying healing? *Ann Emerg Med* 2003;41(1):134-40.
- [22] Elkington AR, Khaw PT. ABC of eyes. Injuries to the eye. *BMJ* 1988;297(6641):122-5.
- [23] Mukherjee P, Sivakumar A. Tetanus prophylaxis in superficial corneal abrasions. *Emerg Med J* 2003;20(1):62-4.
- [24] Macedo Filho ET, Lago A, Duarte K, et al. Superficial corneal foreign body: laboratory and epidemiologic aspects. *Arq Bras Oftalmol* 2005;68(6):821-3.
- [25] Fleiszig SM, Efron N, Pier GB. Extended contact lens wear enhances *Pseudomonas aeruginosa* adherence to human corneal epithelium. *Invest Ophthalmol Vis Sci* 1992;33(1):2908-16.
- [26] Arbour JD, Brunette I, Boisjoly HM, et al. Should we patch corneal erosions? *Arch Ophthalmol* 1997;115:313-7.
- [27] Wilson SA, Last A. Management of corneal abrasions. *Am Fam Physician* 2004;70(1):123-8.
- [28] Newell SW. Management of corneal foreign bodies. *Am Fam Physician* 1985;31(2):149-56.
- [29] Buttaravoli P, Stair T. Common simple emergencies. 2.12-Removal of dislocated contact lens. Available at: <http://www.ncemi.org/cse/cse0212.htm>. Accessed August 5, 2007.
- [30] Ramponi DR. Eye on contact lens removal. Available at: [http://findarticles.com/p/articles/mi\\_qa3689/is\\_200108/ai\\_n8985396](http://findarticles.com/p/articles/mi_qa3689/is_200108/ai_n8985396). Accessed August 5, 2007.
- [31] Kucklorn R, Kottel A, Schrage N, et al. Poor prognosis of severe chemical and thermal eye burns: the need for adequate emergency care and primary prevention. *Int Arch Occup Environ Health* 1995;67(4):281-4.
- [32] Cheh AI, Reensta-Buras WR, and Rosen C. Burns, ocular. Available at: <http://www.emedicine.com/emerg/topic736.htm>.
- [33] Garcia GE. Management of ocular emergencies and urgent eye problems. *Am Fam Physician* 1996;53(2):565-74.
- [34] Schrage, et al. Eye burns. *Burn* 2000;26:699.

- [35] Langefeld S, Press UP, Frenz M, et al. Use of lavage fluid containing diphoterine for irrigation of eyes in first aid emergency treatment. *Ophthalmologie* 2003;100(9):727-31 [Article in German].
- [36] Kompa S, Redbrake C, Hilgers C, et al. Effect of different irrigating solutions on aqueous humour pH changes, intraocular pressure and histological findings after induced alkali burns. *Acta Ophthalmol Scand* 2005;83(4):467-70.
- [37] Saidinejad M, Burns MM. Ocular irrigant alternatives in pediatric emergency medicine. *Pediatr Emerg Care* 2005;21(1):23-6.
- [38] Ikeda N, Hayasaka S, Hayasaka Y, et al. Alkali burns of the eye: effect of immediate copious irrigation with tap water on their severity. *Ophthalmologica* 2006;220(4):225-8.
- [39] Jones JB, Schoenleber DB, Gillen JP. The tolerability of lactated Ringer's solution and BSS plus for ocular irrigation with and without the Morgan therapeutic lens. *Acad Emerg Med* 1998;5(12):1150-6.
- [40] Ernst AA, Thomson T, Haynes M, et al. Warmed versus room temperature saline solution for ocular irrigation: a randomized clinical trial. *Ann Emerg Med* 1998 Dec;32(6):676-9.
- [41] Haddad C. Central retinal artery occlusion. Available at: <http://www.eyeweb.org/CRAO.htm>. Accessed August 5, 2007.
- [42] Graham RH, Huang E, Kim DB, et al. Central retinal artery occlusion. Available at: <http://www.emedicine.com/OPH/topic387.htm>.
- [43] Peak DA. Acute orbital compartment syndrome. Available at: <http://www.emedicine.com/emerg/topic881.htm>.
- [44] Legome E, Pancu D. Future applications for emergency ultrasound. *Emerg Med Clin North Am* 2004;22:817-27.
- [45] Blaivas M, Theodoro D, Sierzenski PR. Elevated intracranial pressure detected by emergency ultrasonography of the optic nerve sheath. *Acad Emerg Med* 2003;10(4):376-81.
- [46] Tayal VS, Neulander M, Norton HJ, et al. Emergency department sonographic measurement of optic nerve sheath diameter to detect findings of increased intracranial pressure in adult head injury patients. *Ann Emerg Med* 2007;49(4):508-14.
- [47] Tsung JW, Blaivas M, Cooper A, et al. A rapid noninvasive method of detecting elevated intracranial pressure using bedside ocular ultrasound: application to 3 cases of head trauma in the pediatric emergency department. *Pediatr Emerg Care* 2005;21(2):94-8.